

CABINETELE MEDICALE Dr.BURLOIU s.r.l.

Patient: Korkmaz Sara Maria, 3 month 28 days.

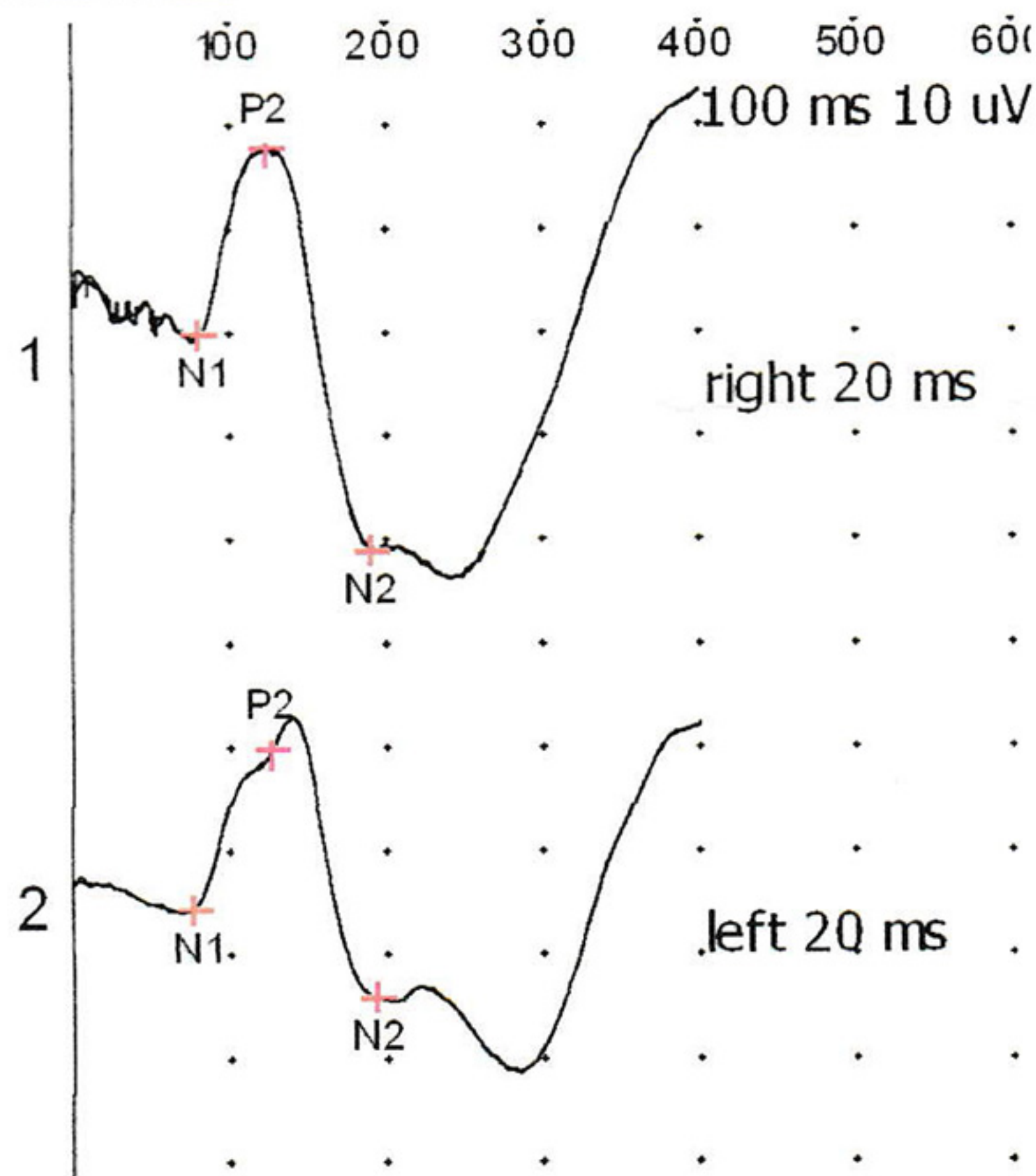
Date: 13.05.2010.

Diagnosis: AO nistagmus congenital

Doctor: A. Burloiu

1. Visual flash EP

1ch: F-O



Latencies

Stimulus	Chan-nel	Compo-nent	Lat., ms	Norm, ms	Dev., %
right eye 20 ms	1	N1	80	73	(N)
		P2	123	103	+19.8
		N2	190	128	+48.4
left eye 20 ms	1	N1	76.6	73	(N)
		P2	127	103	+22.9
		N2	193	128	+51.1

Amplitudes

Stimulus	Chan-nel	Compo-nents	Ampl., uV(/)	Norm, uV	Dev., %
right eye 20 ms	1	N1-P2	18	10.1	+78.6
		P2-N2	38.6		
left eye 20 ms	1	N1-P2	15.3	10.1	(N)
		P2-N2	23.9		

Latente alungita la AO cu amplitudini normale sunt sugestive pentru o intirziere in mielinizare a caili optice.

Control la 1 an.

Dr. BURLOIU ADRIAN
Medic Specialist in Oftalmologie